

PRELIMINARY STUDY OF COLLATERAL FLOWS IN PATIENTS WITH AORTIC COARCTATION

Amandine Martin (1), Hervé Corbineau (1), Jean-Philippe Verhoye (1), Mathieu Lederlin (2), Agnès Drochon (3)

1. Service Chirurgie Cardio-Thoracique et 2. Département d'Imagerie Cœur-Vaisseaux, CHU PontChaillou 35000 Rennes France; 3. UMR 7338 – UTC - Sorbonne Universités 60200 Compiègne France

Introduction

Coarctation of aorta is a frequent congenital heart disease characterized by a narrowing segment of the aorta just after the left subclavian artery origin. This stenosis causes a new distribution of blood flow into the aortic branches because of a higher arterial pressure before the obstacle and a lower blood flow after. Depending of the severity of the coarctation, this may lead to left ventricular dysfunction, cerebral and aortic aneurysms, ... In some patients, some collateral supply develops to provide blood flow to the descending aorta via the subclavian and intercostal arteries. This study aims to improve the knowledge of these collateral flows, because it is critical in planning the operative approach.

Methods

Four adult patients underwent a surgical correction of aortic coarctation in the Thoracic and CardioVascular Department at University Hospital of Rennes, and had given informed consent for this study. They had a tomodynamometry of the thoracic aorta before and after surgery, giving anatomical data, such as aortic diameters and areas. The shape of the thoracic aorta (more or less angulated) was also precised. A cine phase-contrast magnetic resonance imaging (PC-MRI) was performed for every patients. This examination was chosen because of its non-invasive aspect and its hemodynamic performance with cardiac gating. Five locations in the aorta were selected to collect hemodynamic data: 1: ascending aorta (flow rate Q_1); 2: distal aortic arch, just after left subclavian artery (Q_2); 3: coarcted segment of the aorta (native or repaired) (Q_3); 4: proximal segment of the descending aorta, after the coarcted zone (Q_4); 5: distal segment of the descending aorta, at the diaphragm level (Q_5). So that Q_1 - Q_2 represents the flow rates directed towards aortic arch branches, and Q_5 - Q_4 represents the amount of collateral flow delivered to the distal descending thoracic aorta.

Results

Some typical measurements of the flow rates Q_1, \dots, Q_5 are illustrated in Figure1, for one of the patient of the study, after surgery.

This patient (F, 45 years old) had a 40 mmHg coarctation pressure drop before surgery, and she underwent a full aortic reconstruction. After surgery, she presents an harmonious decrease (and sliding in time) of the flow rates along the aorta, and no more collateral flow is detected ($Q_4 > Q_5$). For this patient, the diameters (cm) of the aorta after surgery were $D_1 = 2.86$, $D_2 = 2.57$, $D_3 = 2.23$, $D_4 = 1.92$, $D_5 = 1.85$, yielding peak systolic aortic velocities of the order of 60 cm/s, and peak Reynolds number of 3500.

Discussion

The recorded data for all the patients included in the study are in very good agreement with the literature [1, 2]. They could allow to develop a lumped parameter model similar to the existing model of Keshavarz-Motamed [3], in which the collateral pathways may be more precisely represented.

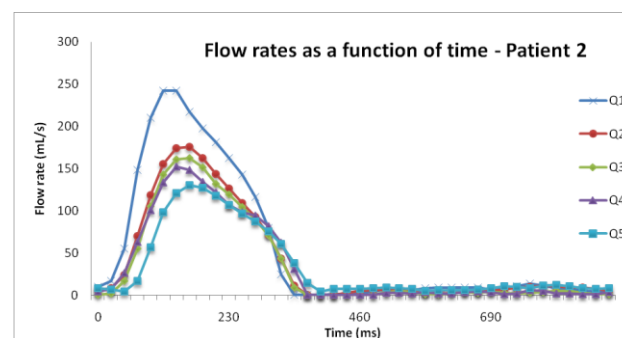


Figure1: Flow rates recordings at different locations along the aorta, after surgery, for one of the patient of the study

References

1. Itu et al., Ann. Biomed. Eng., 41:669-681, 2013.
2. Hope et al., J. Magn Res Imag, 31:711-718, 2010.
3. Keshavarz-Motamed et al., J. Biomech., 48:4229-4237, 2015.

